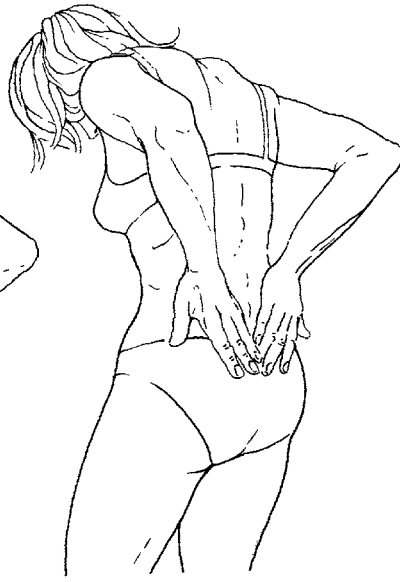
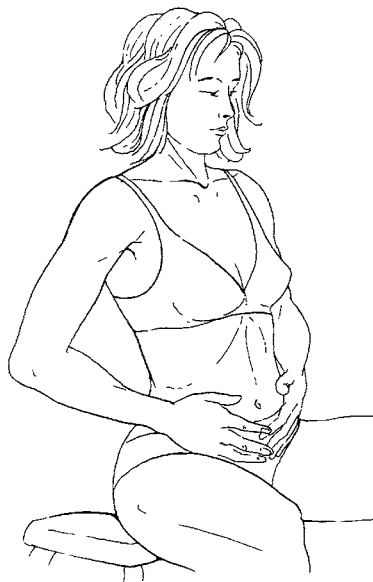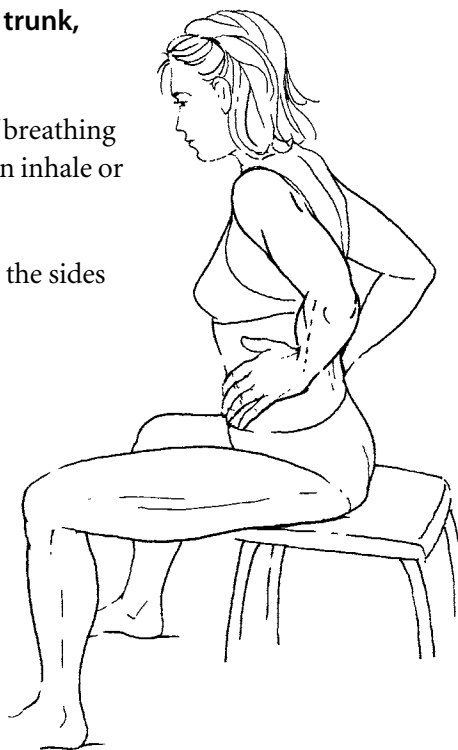


**Breathing can cause movement in any part of the trunk,
but the air goes only into the lungs**

Whether it is costal or abdominal breathing, the act of breathing can affect almost all regions of the trunk. Thus, you can inhale or exhale while feeling movement, for example:

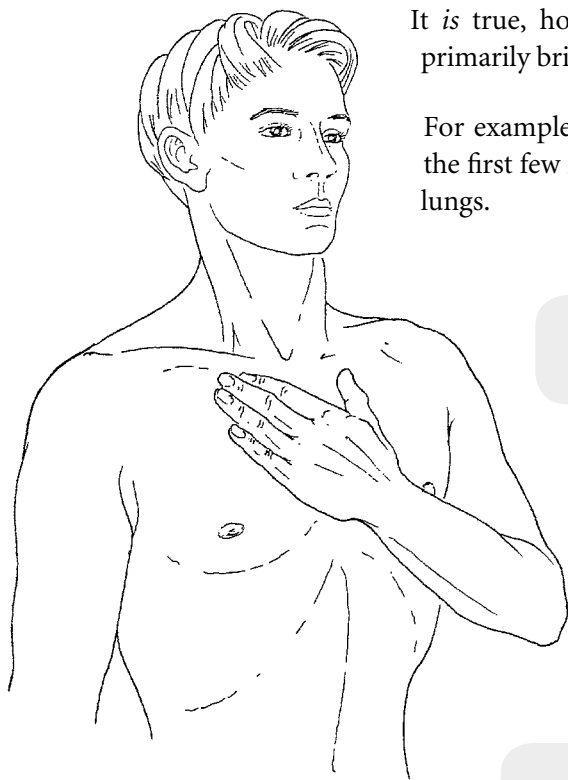
- at the front of the ribs, but also at the back or on the sides
- higher or lower in the rib cage
- around the waist
- at the front of the abdomen (at different levels)
- further down in the region of the pelvis, either in the front or back, or in the perineum.



This is why we talk about breathing into your belly, into the clavicles, the back, and so forth. Of course, the inhaled air does not actually reach all parts of the body that are moved during breathing; even when you inhale very deeply, the air never goes anywhere but to the lungs, which occupy only a small portion of the thorax.

It is true, however, that certain types of breathing will primarily bring air into certain areas of the lungs.

For example, very shallow breathing, which causes only the first few ribs to move, more readily fills the top of the lungs.

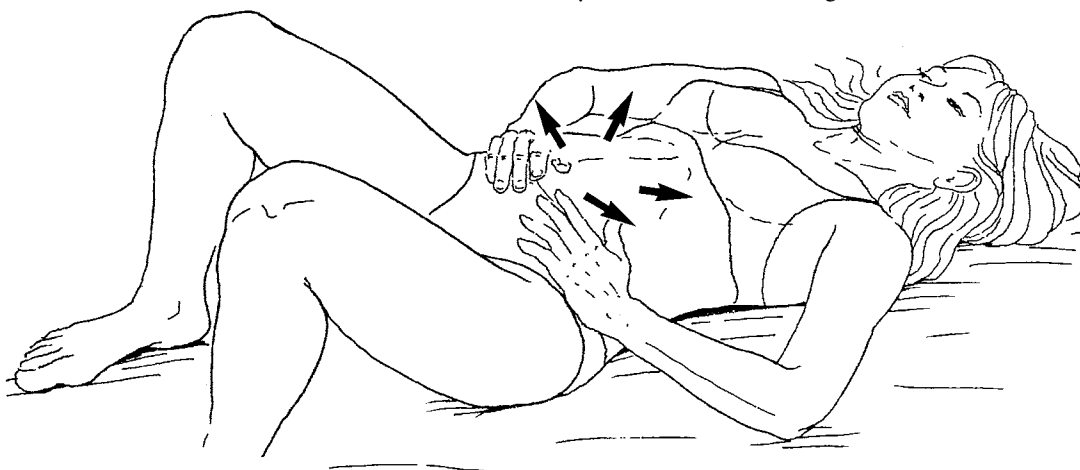

People sometimes say:
“Breathe into your neck.”

Abdominal breathing, however, primarily brings air into the base of the lungs.

People sometimes say:
“Breathe into your belly.”

But even here, the air does not go anywhere but to the lungs.

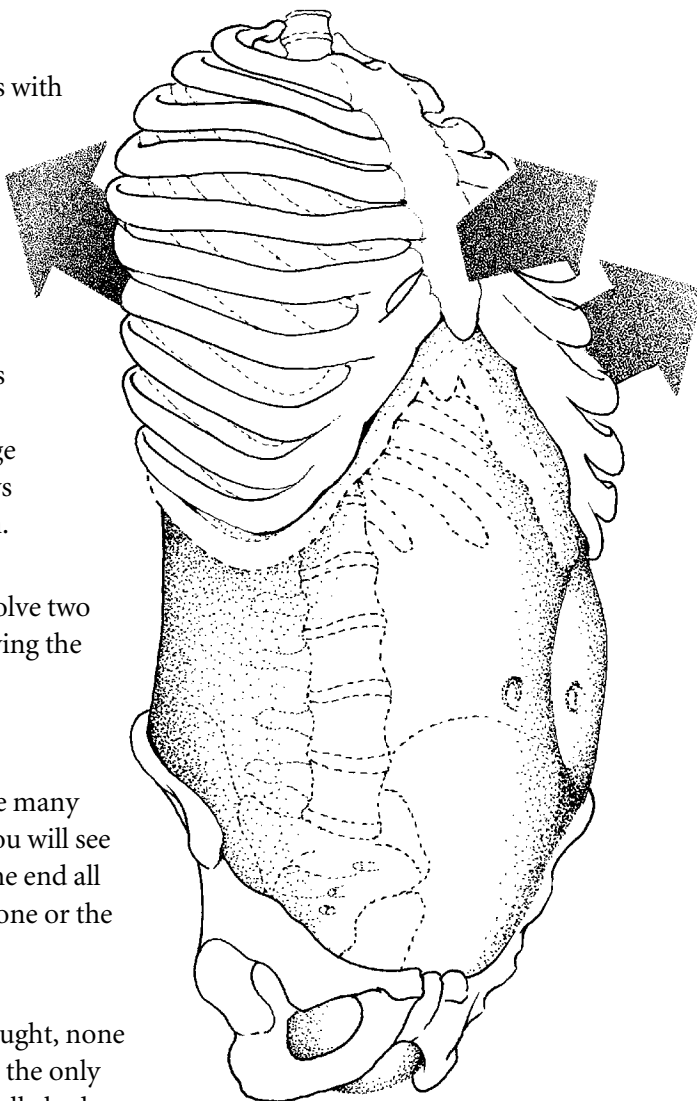


That is why it is important not to confuse the location where the airflow occurs, which is always in the lungs, with the locations where movement is felt in the trunk, because of the act of breathing itself or the type of breathing that is used.

TWO TYPES OF BREATHING

There are two principal types of breathing:

- *Costal breathing:*
This is breathing that works with the ribs. It opens them during inhalation and closes them during exhalation.
- *Diaphragmatic breathing:*
This is breathing that works with the abdominal area. It causes the abdomen to bulge during inhalation and draws it back in during exhalation.



These two types of breathing involve two completely different ways of moving the lungs.

You can mix and match them in different ways, and thereby create many variations of breathing. But, as you will see over the course of this work, in the end all of these variations come back to one or the other principal type of breathing.

Contrary to what is sometimes taught, none of these variations in breathing is the only good one, and none of them is really bad.

They just fit different circumstances and can be used for different purposes. Therefore, it is important to practice a variety of breathing techniques, especially when you realize that you have a tendency to use one technique all the time.

RESPIRATORY VOLUMES

During both inhalation and exhalation, breathing occurs with different amplitudes, which is to say, different volumes of air.

In practice, the volume of airflow through the lungs is never the same from one breath to the next. This is due to variations in activity and thus to different demands for oxygen. The most regular volume exchange occurs while sleeping. Apart from that, we can identify several characteristic volumes.

It is important to clearly distinguish among different types of volume, and to recognize them as they occur in a particular physical exercise. Why? Because the mechanics of breathing are very different for each volume, the effects will be different too.

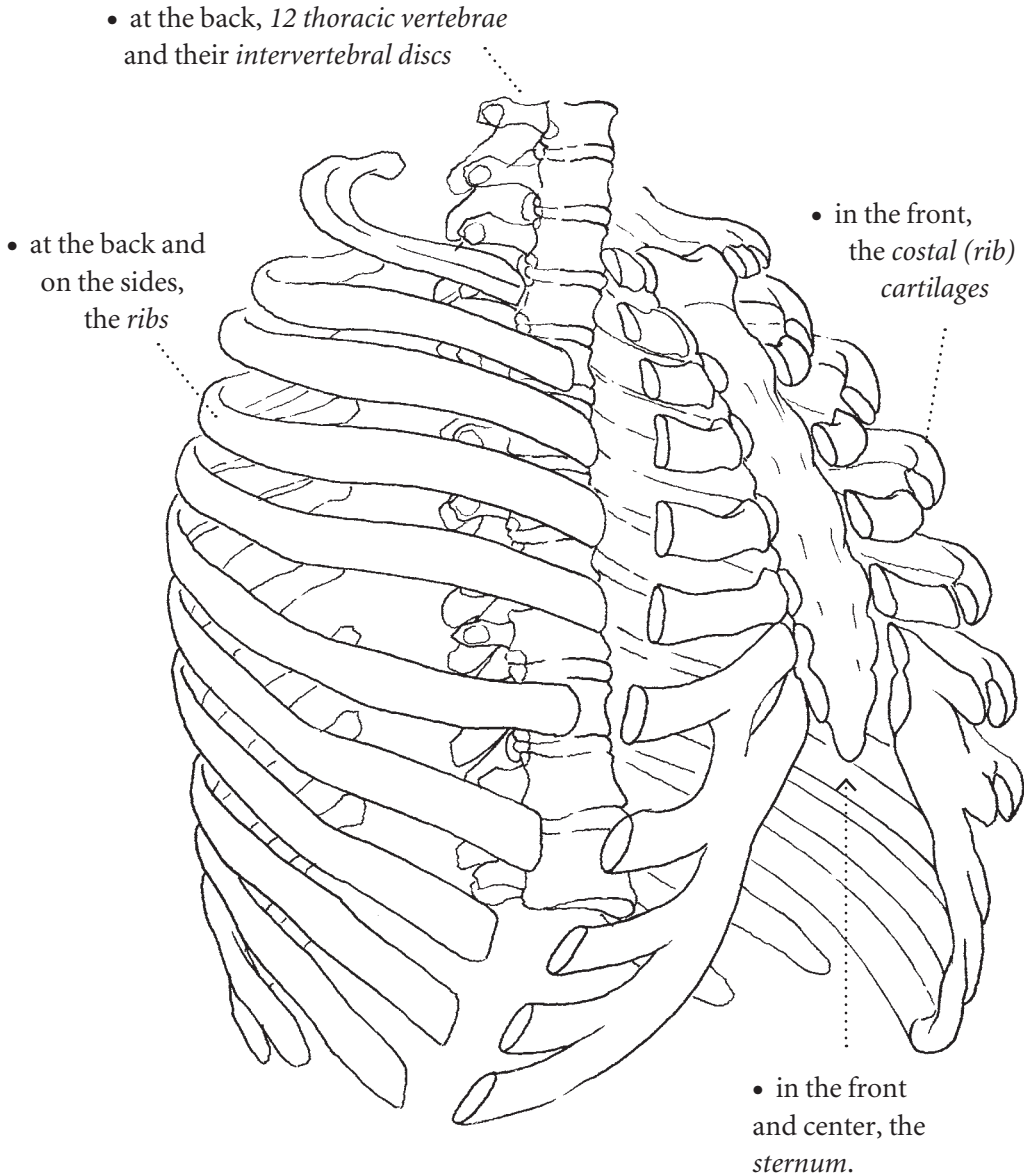
Now, we often string together or combine different types of volume, even within the same breath, without being aware of it; this makes it hard to interpret what is actually happening. It is therefore a good idea to have a clear understanding of what a volume is, first by identifying each individual volume, and then by recognizing them in the course of several breaths strung together.

Later, you will find out which forces play a role within each respiratory volume. This is described on pages 117-124.

In the end, you will understand how all these details work together during the execution of a breath. This is basic information that will help you adapt your breathing in real time to perform a specific movement or achieve a certain goal. That is why in the course of this book I refer frequently to the notion of volume.

THORACIC CAGE AS A WHOLE

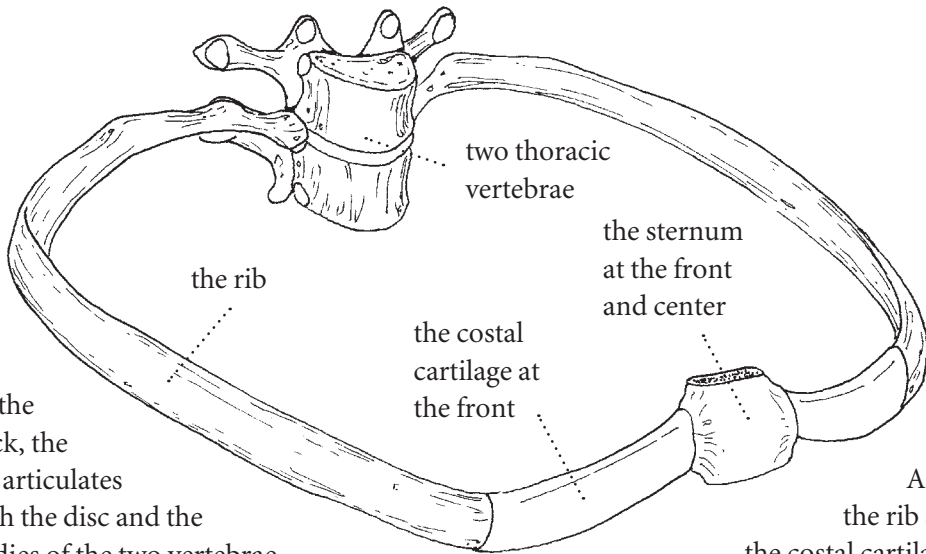
The thoracic cage consists of a number of elements:



These elements are not completely bony. Some of them belong to other functional structures. For example, the thoracic spine belongs to the spinal column, and the sternum is part of the shoulder girdle.

COSTAL ARC AND ITS ARTICULATIONS

Respiratory studies sometimes refer to the *costal arc*. This is not the same as a rib. The complete costal arc consists of:



At the back, the rib articulates with the disc and the bodies of the two vertebrae, but also with the transverse process of the vertebra below. These are truly mobile articulations.

At the front, the rib attaches to the costal cartilage, which, in turn, attaches to the sternum. These are simple structural junctions.

The costal arc varies, depending on the rib level

The first one is especially small. At that level, the two arcs on the right and on the left outline the circle that the bottom of the neck forms with the top of the sternum.

The arcs of the 8TH through 10TH vertebrae are the largest and most flexible, considering the size of the rib and the costal cartilage.

The two last arcs are not complete because there is no costal cartilage at that level.

The costal arc is mobile

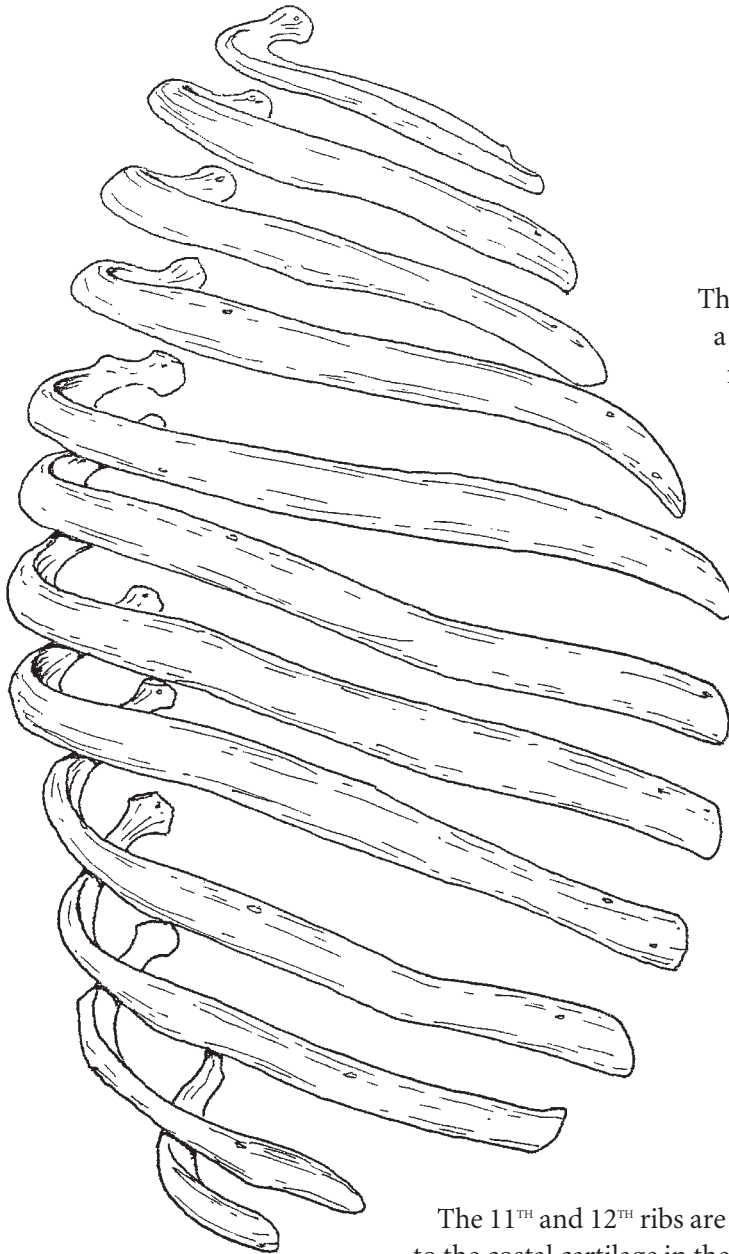
Its overall mobility is due to the mobility of each of its elements. It comprises the individual flexibility of each rib and the costal cartilage (see pages 41 and 42), but also the mobility of the costovertebral articulations (pages 47 and 48) and of the intervertebral articulations (pages 45 and 46). When working with the mobility of the costal arcs, all of these structures must be taken into account (see practice pages 162-165).

RIBS

The thoracic or rib cage consists of 12 pairs of ribs, which give it its shape.

They increase in length from the first to the 10th rib,

then decrease in length from the 11th to the 12th.



The first rib has a shape that is flattened from top to bottom,

the other ribs are flattened from the inside toward the outside.

The 11th and 12th ribs are not attached to the costal cartilage in the front. They are called “floating” ribs.

The individual rib

Each rib is a flat, flexible bone which consists of several parts:

a narrow portion, called the *neck*,

a knoblike structure, called the *tubercle*.

the *head* at the back

Each rib makes a curve, which outlines the thorax, making a "bucket handle" around it while twisting around itself.

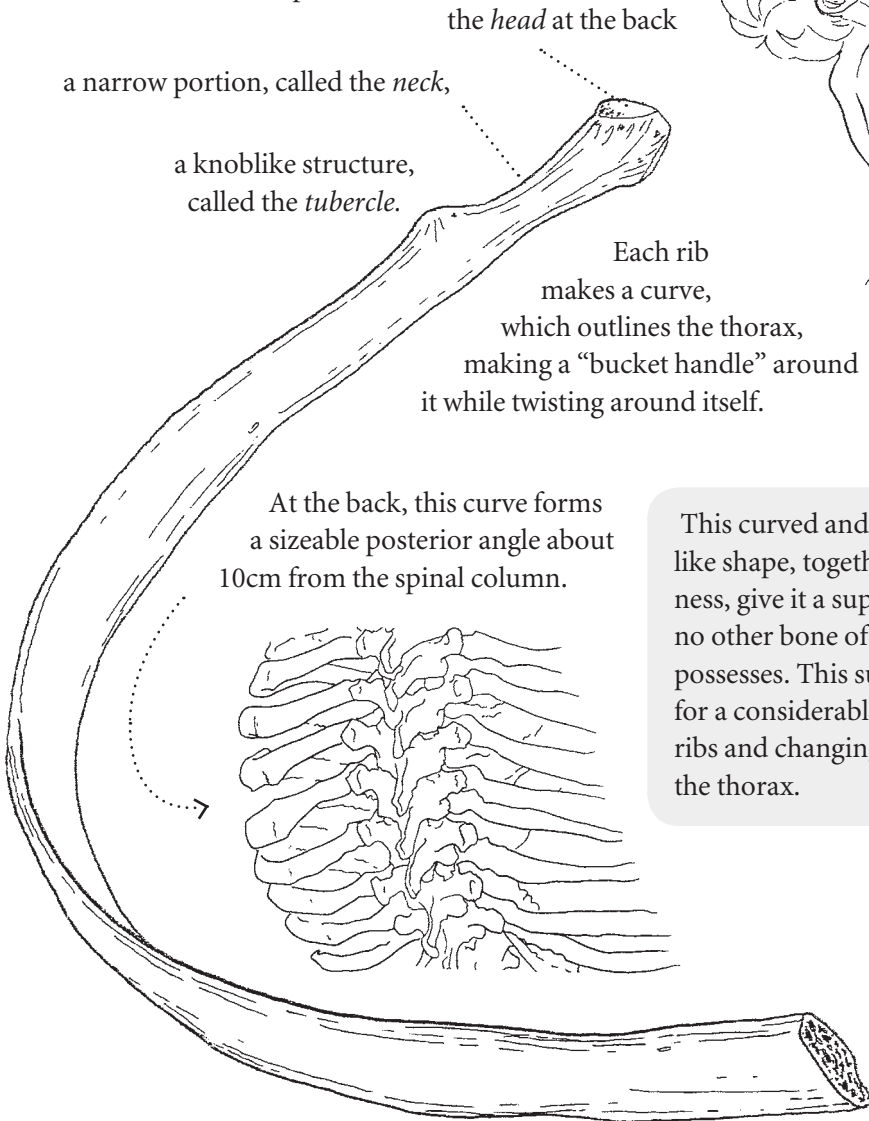
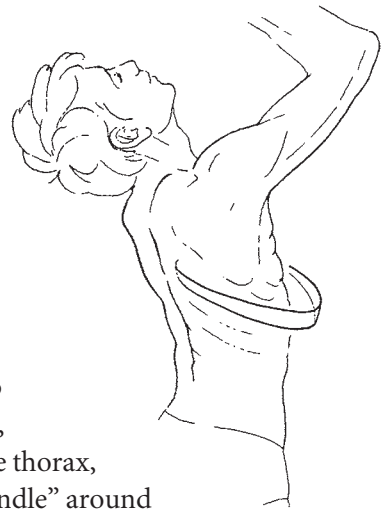At the back, this curve forms a sizeable posterior angle about 10cm from the spinal column.

This curved and twisted blade-like shape, together with its thinness, give it a suppleness that no other bone of the skeleton possesses. This suppleness allows for a considerable bending of the ribs and changing of the shape of the thorax.

At the front, the rib has a facet which articulates with the costal cartilage.

The rib has considerable elasticity. After bending, it returns to its original shape. We will see that this elasticity sometimes contributes to the act of breathing, both during inhalation and exhalation.

The elasticity and suppleness of the ribs are maintained by movement, especially, but not exclusively, the movement of breathing. You can also actively or passively bend the ribs without breathing. (To maintain suppleness of the ribs, see practice pages 162-164.)

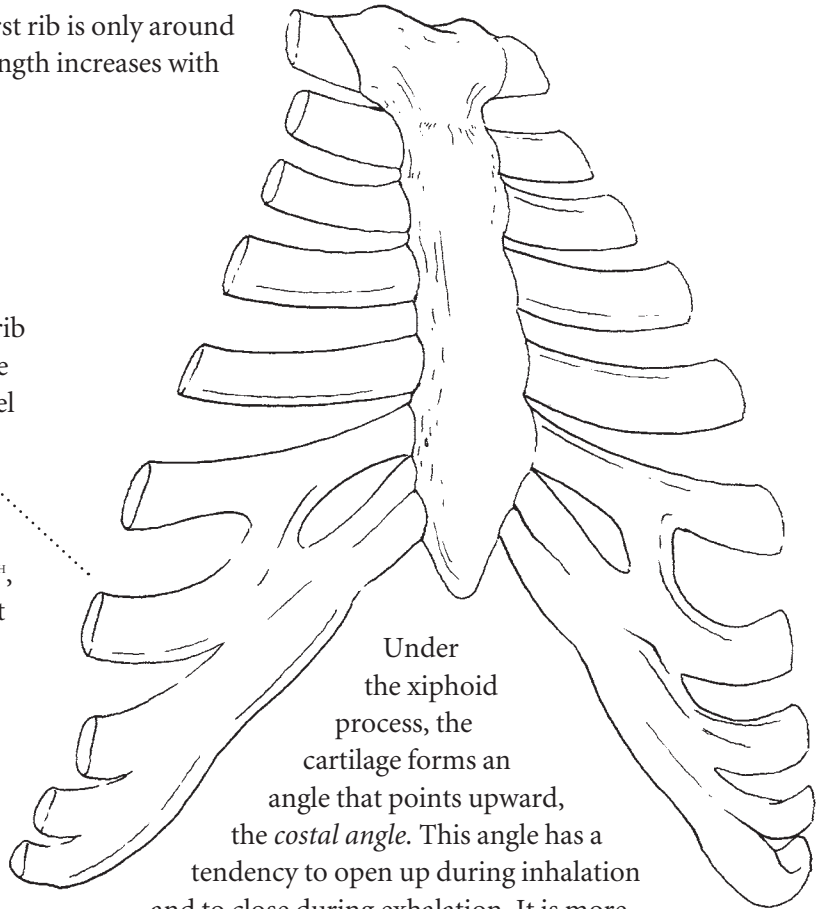


At the front, the ribs are attached to the sternum via the costal cartilage. The cartilage has the same curvature as the ribs. It consists of hyaline cartilage tissue, which is more supple and more elastic than bone tissue. That is why the area at the front of the thorax, to the left and right of the sternum, is more flexible, and permits greater amplitude in the act of breathing.

The cartilage of the first rib is only around 1cm in length. This length increases with each subsequent rib.

The cartilage of each rib directly attaches to the sternum, until the level of the 7th rib.

The cartilage of the 8th, 9th, and 10th ribs is not directly attached to the sternum. Instead, it is attached to the cartilage of the 7th rib. The cartilage of these ribs is therefore much longer and constitutes a mobile, deformable area at the bottom front of the thorax.

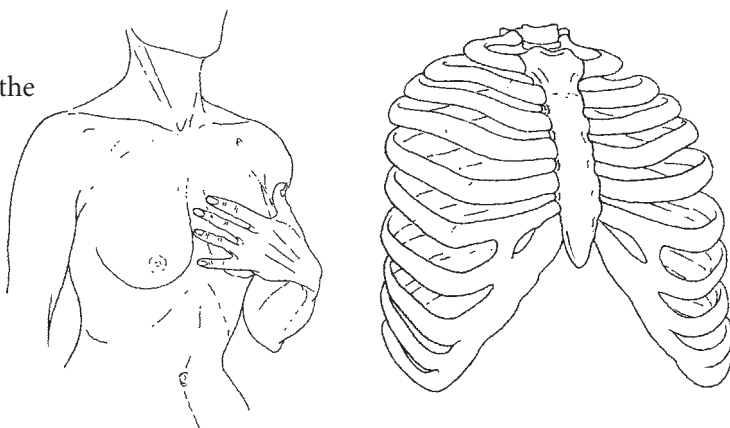


Under the xiphoid process, the cartilage forms an angle that points upward, the *costal angle*. This angle has a tendency to open up during inhalation and to close during exhalation. It is more or less open in each individual, independent of breathing, which helps one determine the respiratory type of each person.

The suppleness of the costal cartilage adds to the suppleness of the ribs and the mobility of the costal and vertebral articulations. This is important to the amplitude and quality of breathing. The suppleness starts to decline as a person ages or if he or she lacks thoracic mobility. Conversely, it can be sustained by practicing breathing and non-breathing movements in the thoracic area (see practice pages 162-164).

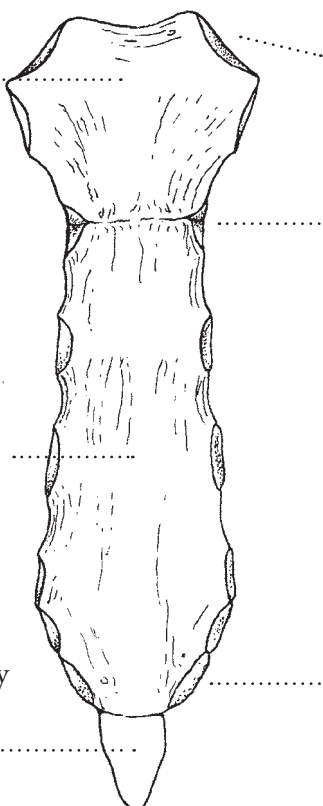
STERNUM

The sternum is located at the upper, middle section of the rib cage. It is a flat bone, which is in a vertical position when a person is standing, and has the shape of a sword blade. It consists of three parts:



On its sides, the sternum has notches where the costal cartilage connects; this is called the costosternal junction.

- At the top is the *manubrium*, which articulates with the first two ribs.



The first pair of notches are the clavicular notches, where the clavicles sit on the sternum.

The third pair of notches (for 2nd rib) are found at the junction of the manubrium with the body of the sternum. This junction is called the *angle of Louis*.

- The middle section, the longest, is the *body*, which articulates with ribs 3-7.

- The inferior pointy end is called the *xiphoid process*.

The 7th notch, which is a bit larger than the others, connects with the costal cartilage of the 7th rib, which then connects with the cartilage of ribs 8 through 10.

The sternum is an important landmark for observing and palpating respiratory movements. It can be moved vertically or obliquely to varying degrees, revealing how the diaphragm acts on the rib cage and how the inspiratory rib cage muscles work (see practice pages 190, 198, and 201).

MUSCLES OF INSPIRATION

These are the muscles that help *increase the volume of the lungs*. Expansion of the lungs can occur in two different ways:

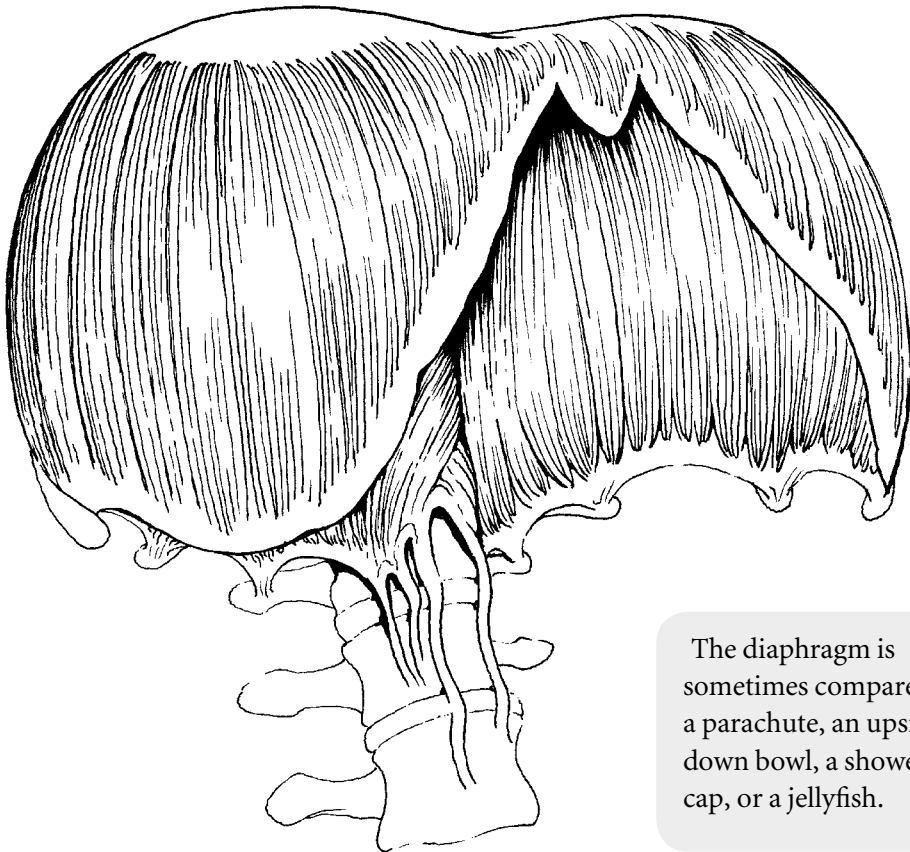
- by applying a pulling action to the base of the lungs
- by applying a pulling action at the anterior, lateral, or posterior surfaces of the lungs.

The first inspiratory muscle that we will look at here is the diaphragm. It can act in both ways.

Diaphragm: primary inspiratory muscle

Most regular breathing occurs because of this muscle. It acts like a pump at the base of the lungs.

The diaphragm is a large muscular and fibrous wall which simultaneously separates and connects the thorax and the abdomen.



The diaphragm is sometimes compared to a parachute, an upside-down bowl, a shower cap, or a jellyfish.

The diaphragm is situated between the organs like a supple layer which fits between them and takes their form. It is shaped like a large, irregular dome, which is very thin and more developed at the back than at the front. Thus, contrary to the impression that you may get from the illustrations, the diaphragm is *not* a rigid dome.

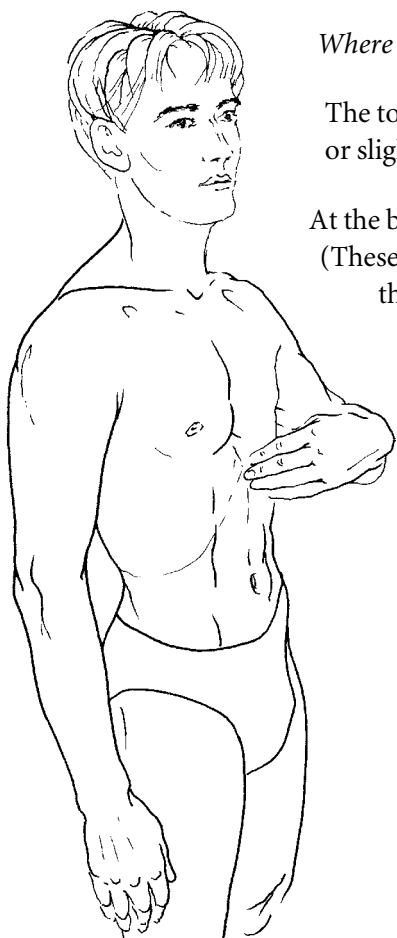
Its edges are attached to the internal outline of the rib cage.

The right half is slightly more curved and higher than the left, especially during a strong exhalation.

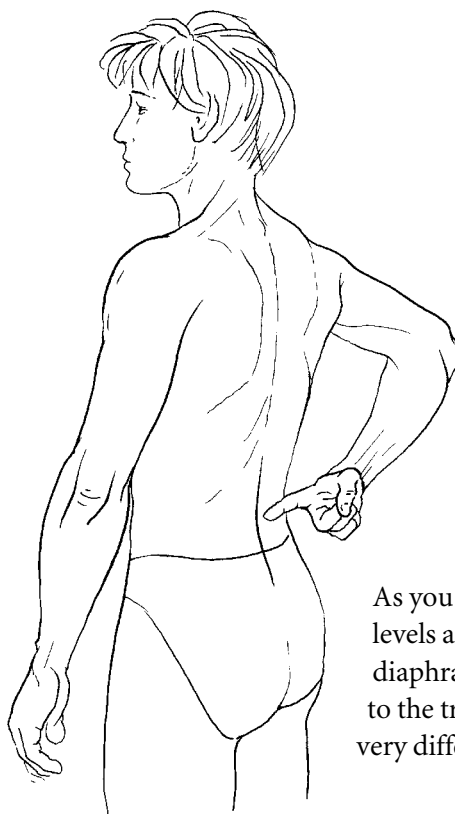
Where in the trunk is the diaphragm located?

The top of the dome is situated at the level of the 4th or 5th rib, or slightly higher than the xiphoid process.

At the back, the top is at the level of the 7th thoracic vertebra.
(These are average measurements, and may vary depending on the position of the rib cage and the extent of inhalation and exhalation.)



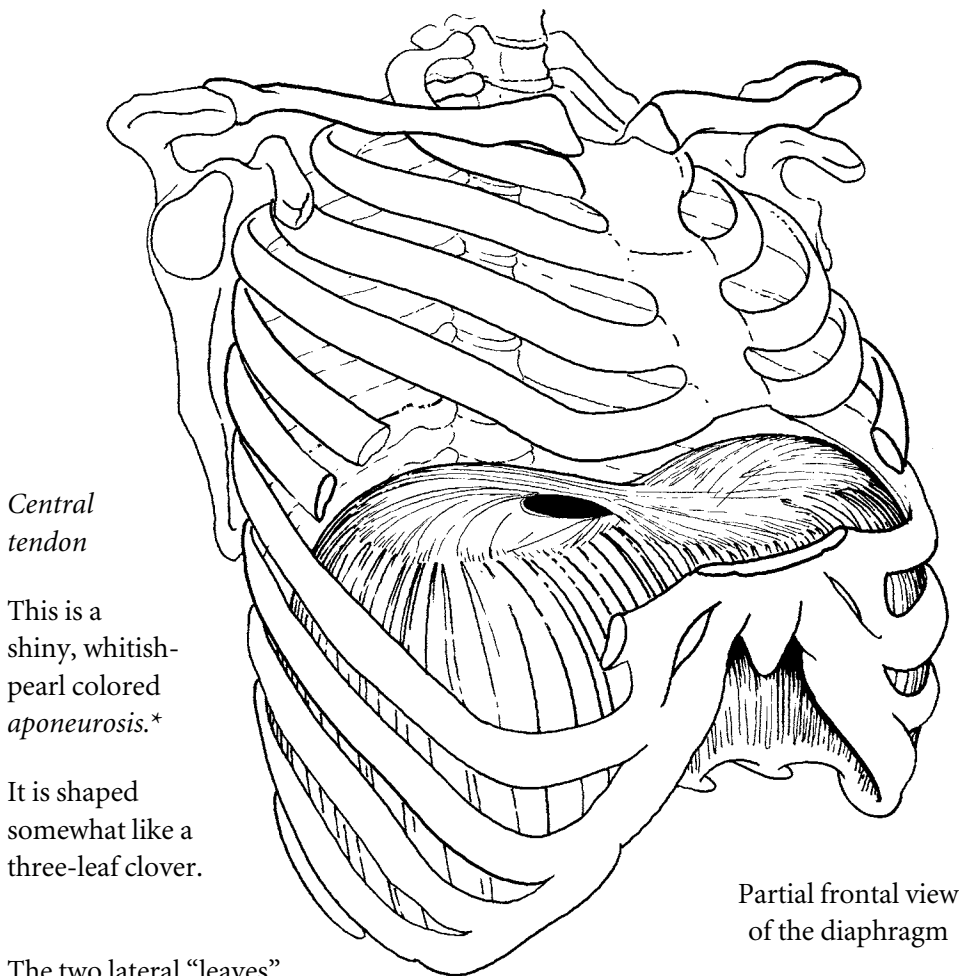
The base of the diaphragm is formed at the back by tendons, which insert into the 3rd lumbar vertebra. This corresponds to the level of the waist.



As you can see, the levels at which the diaphragm attaches to the trunk are very different.

Anatomy of the diaphragm

The diaphragm has a fibrous center part, which is called the *central tendon*, around which are *muscular fibers* arranged in a beam-like fashion. These fibers attach to the entire circumference of the rib cage.



This is a shiny, whitish-pearl colored *aponeurosis*.*

It is shaped somewhat like a three-leaf clover.

The two lateral “leaves” (of the clover) are located more posterior and on each side of an indentation, which corresponds to the spinal column. The middle “leaf” is anterior and located behind the sternum.

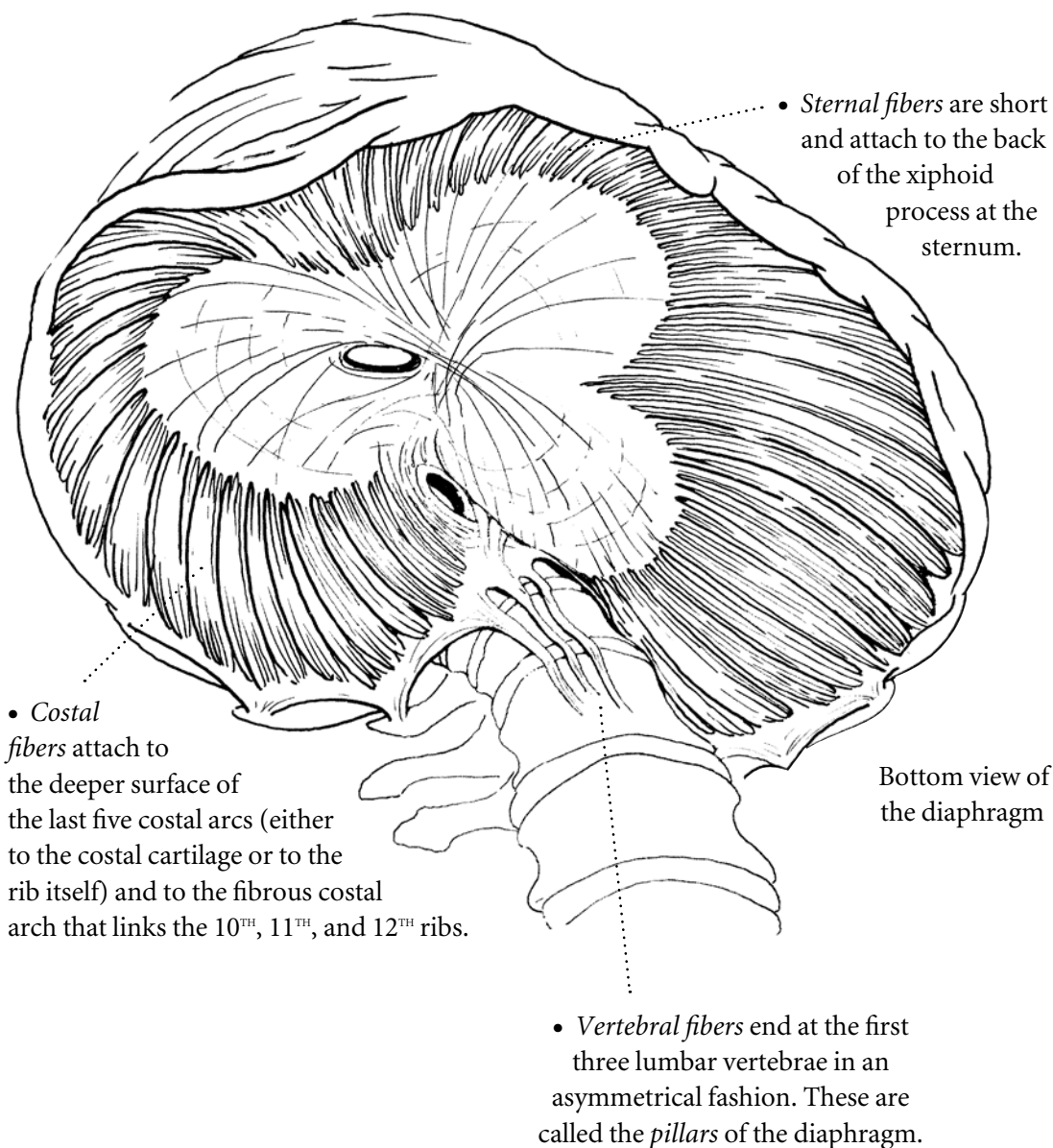
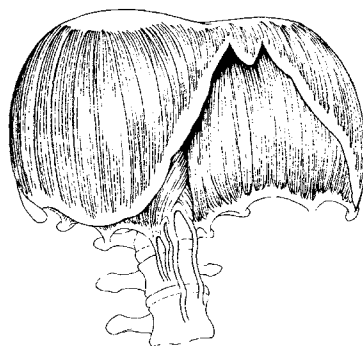
.....

*An aponeurosis is a flexible fibrous tissue that contains numerous collagen fibers which resist pulling. They are arranged in many different directions. An aponeurosis *does not consist of muscular fibers*. Thus, the central tendon is a part of the diaphragm which cannot contract by itself, but is pulled along when the other muscular fibers of the circumference contract. This area passes on the pulling action to other organs that are further away.

Muscular fibers

Muscular fibers originate at the central tendon. They then head down while flaring out and joining the circumference of the rib cage. They form a circular arch, which gives the diaphragm its dome-like shape.

These fibers have different names depending on where they attach:

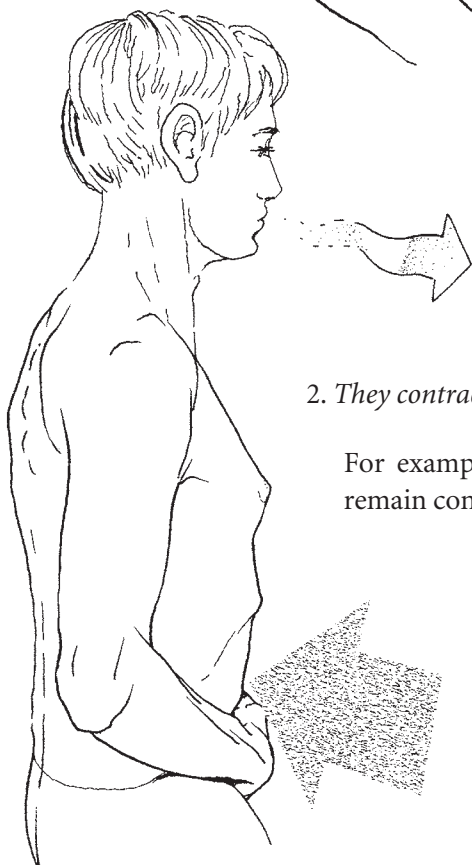
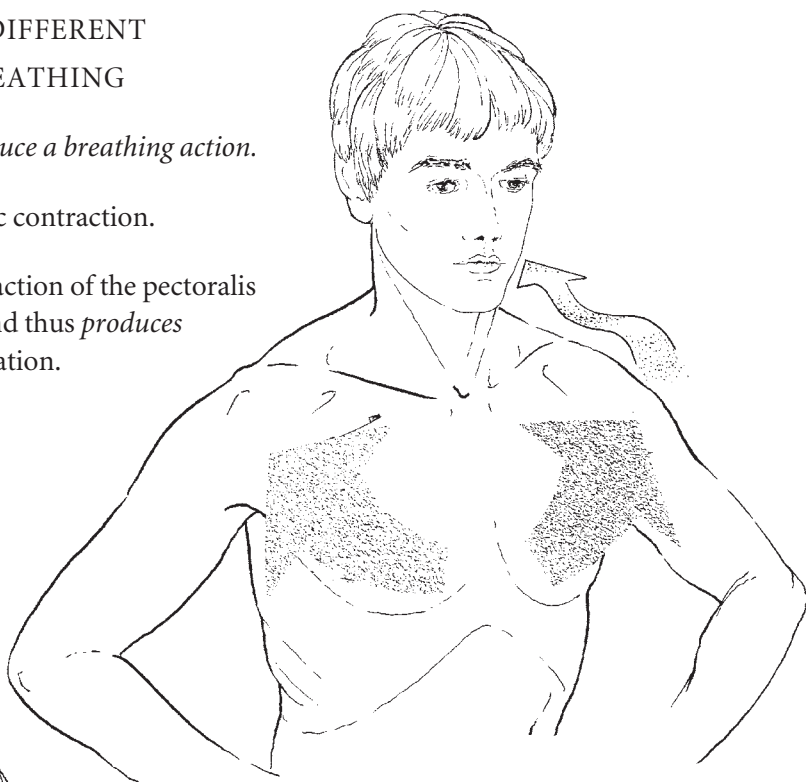


MUSCLES ACT IN DIFFERENT
WAYS DURING BREATHING

1. *They contract to produce a breathing action.*

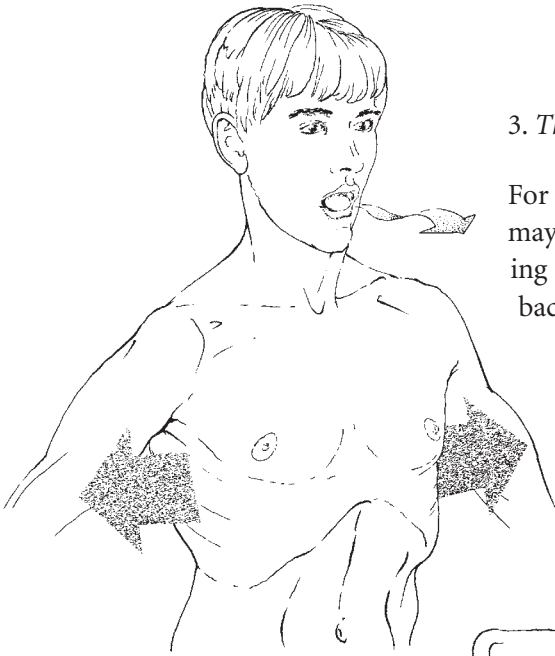
This is called concentric contraction.

For example, the contraction of the pectoralis major raises the ribs, and thus *produces* an anterior costal inhalation.



2. *They contract to maintain a breathing position.*

For example, after a deep exhalation, the abdominal muscles remain contracted to *maintain* an apnea of ERV.

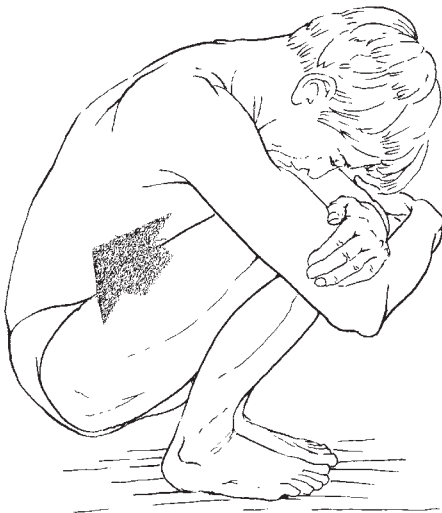
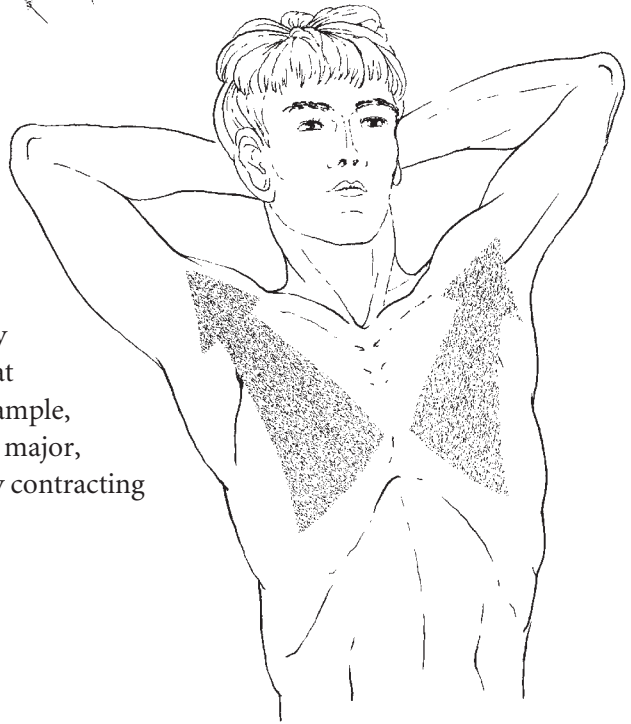


3. They contract to restrain a breathing action.

For example, after a deep inhalation (IRV), you may choose to exhale slowly. To do this, a restraining contraction of the pectoralis major can hold back the elasticity of the lungs.

4. They sometimes act by means other than contraction:

- because they are *stretched*, that is, they are already tense due to a movement at either one of their extremities. For example, lifting the arm stretches the pectoralis major, pulling on the ribs without necessarily contracting itself.

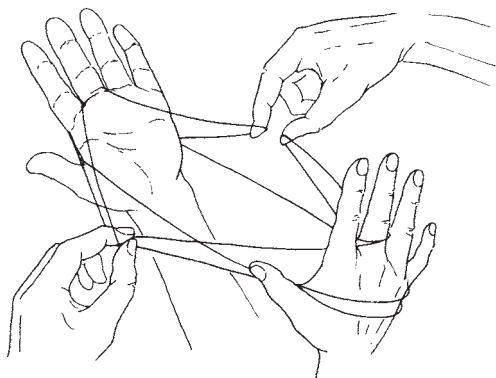


- because of their *viscoelastic mass*, which sometimes acts as a counterweight. For example, when you are in a crouched position and want to inhale with your diaphragm, the anterior thigh muscles press on the abdomen and prevent it from expanding forward, sending the movement to the back.

PULMONARY ELASTICITY: AN IMPORTANT FORCE IN BREATHING


We have seen on page 61 that, from a mechanical standpoint, the lungs behave like a rubber band. More than a string, they are like a rubber band in three dimensions, like playing cat's cradle.

The lungs allow for a certain opening movement when a force from the outside stretches them. This is called pulmonary expansion. But at the same time, they resist this type of stretching, and as soon as the force ends, they return to their original shape.



When we refer to “pulmonary elasticity” in this book, we look at both lungs and regard them as a single elastic entity.

Elasticity in “3-D”

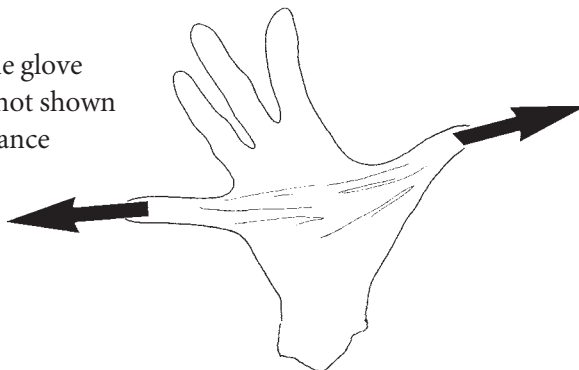


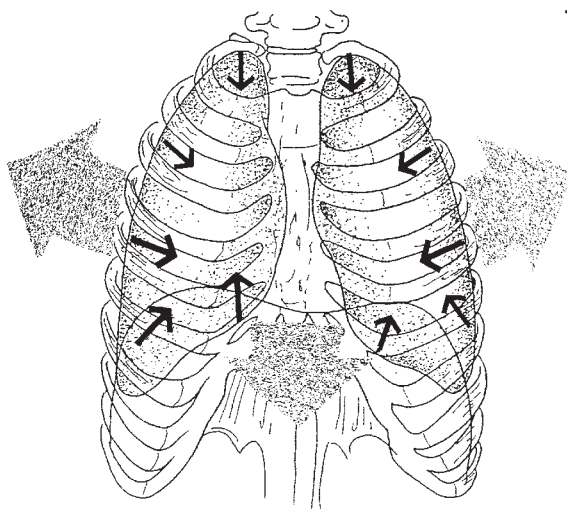
One way to visualize the elasticity of the lungs is to take a kitchen glove and try to stretch it apart. To see how this works in the body, ask a few people to pull each finger of the glove in a different direction.

With two hands, stretch the glove apart, one hand pulling upward, the other downward. This vertical aspect of pulmonary elasticity causes a resistance which tries to pull the first hand downward and the second upward. This is how to visualize the elastic action between the top of the rib cage and the base of the rib cage (the diaphragm).

With two hands, stretch the glove sideways. This is the resistance of the lungs when they are subjected to lateral pulling forces. This is how to visualize the elastic action of the lungs between the lateral walls of the rib cage.

Now use one hand to pull the glove forward and the other to pull it backward (not shown here). This is how to visualize further resistance of the lungs, which will take the first hand backward and the second forward.





The lungs resist inhalation

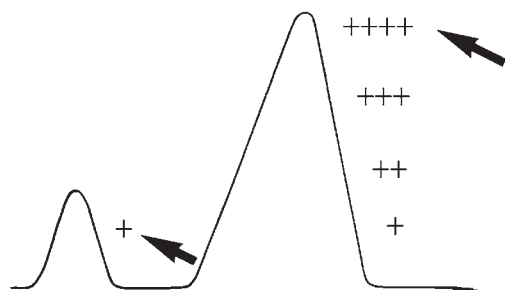
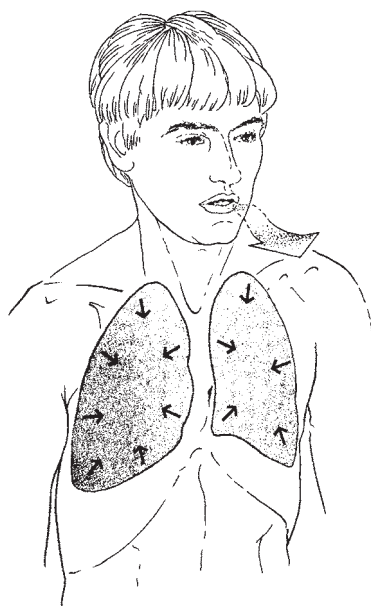
In most breathing actions, a certain force must be applied to open and stretch the lungs, since they resist such stretching. It can therefore be said that the lungs, elastically speaking, more or less resist an inhalation depending on the respiratory volume (see pages 118 and 120).

This is often visualized as the lungs being the force that opens the rib cage.

The lungs as the primary force of expiration

Most exhalations are caused by the elasticity of the lungs.

Thus, the force applied to expiration is mostly an elastic force, rather than a muscular one. This, of course, is more or less true depending on the respiratory volume involved (see pages 117 and 123). However, this elastic force alone cannot completely empty the lungs. When, because of their elasticity, they return to their original shape, they still have a lot of air inside. This is the residual volume (RV).



The elastic force of the lungs varies.

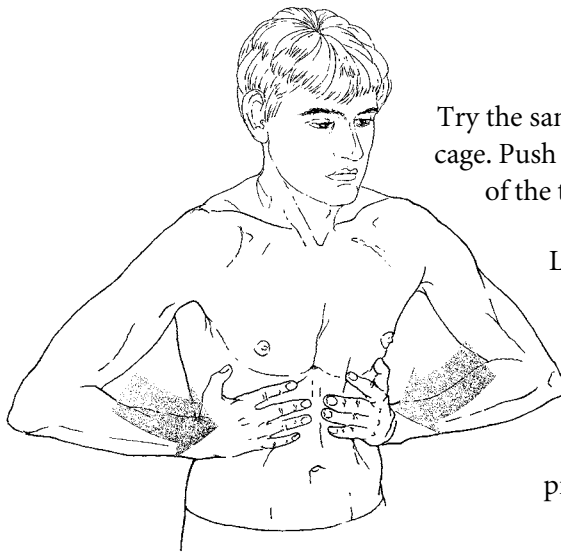
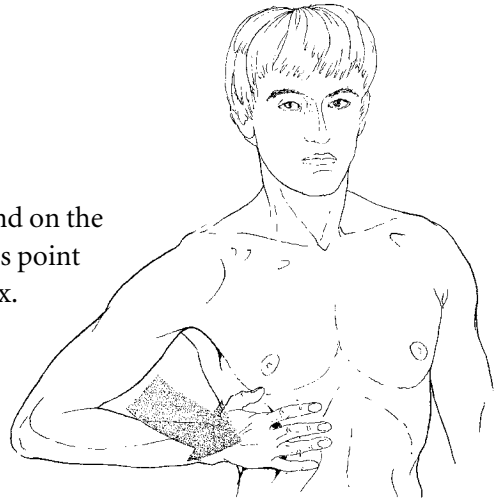
The force that returns the lungs to their original shape is very powerful, especially when the lungs are stretched. For example, it is more powerful after an IRV than after an inhalation of tidal volume.

This force of elastic recoil also contributes indirectly to many other actions that are unrelated to breathing. It can, for example, suck in the belly, mobilize the organs, pull in the ribs, bend the lumbar vertebrae, or bend the cervical region.

1. Curving the ribs

Pushing the ribs with the hands

In standing position, put the palm of your right hand on the right side of your ribs. Feel how you can push at this point in particular and deform the curvature of the thorax.



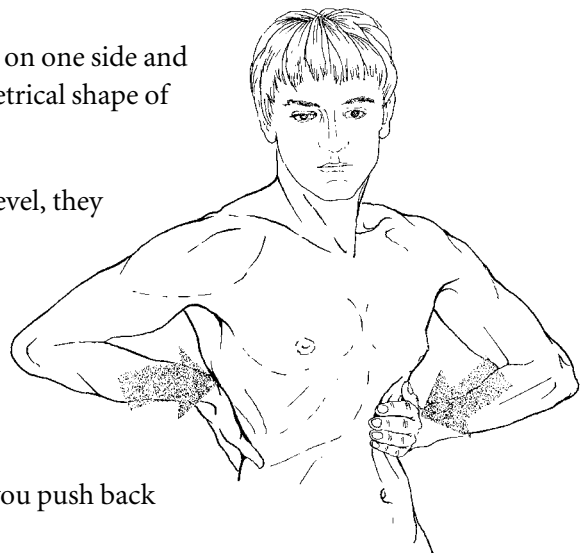
Try the same action with a hand on both sides of the rib cage. Push the ribs on the right and left toward the center of the thorax. This will narrow the thorax.

Look for the same effect in the front, on each side of the costal angle. Press from front to back, or from right to left. This is the area where the longest and most flexible costal cartilages are located. Then feel for the ribs at the back just above the waist and press again. This may be a little more difficult.

Now try to press simultaneously backwards on one side and forward on the other to produce an asymmetrical shape of the costal “cylinder.”

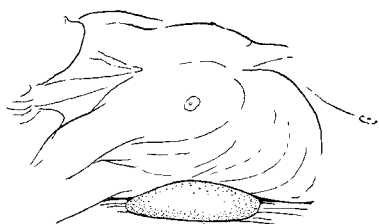
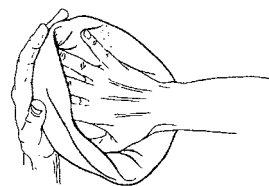
When you try to press the ribs on a higher level, they may seem more rigid. For these less mobile areas of the rib cage, the exercises on the following pages are more effective. The ribs there are moved more easily by pressing against a support to apply counter pressure.

You can use the backrest of a chair to help you push back the ribs in all different directions.



Placing an object under the ribs

For this, you need a soft object with the shape of a half-inflated ball. (A cushion may also be used.) Stretch out on the floor. Observe the contact and support points of your thorax on the floor.

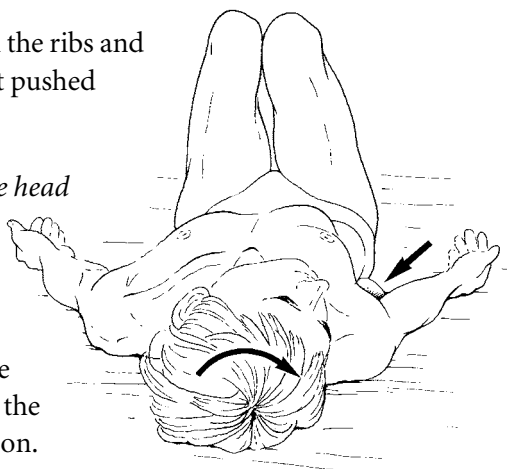


Now place the soft object under your right ribs at mid-level, at about the lower margin of the shoulder blade and a little bit below. Place it 10cm (4 inches) away from the spine, so that it juts out from under your ribs.

Take the time to get into the right position, to feel the ribs and how they adapt to the uneven surface. Do they get pushed back, and how much do they resist?

Modifying the support under the ribs by moving the head

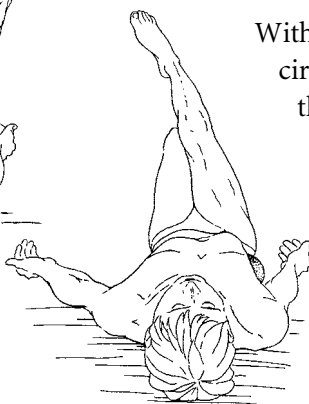
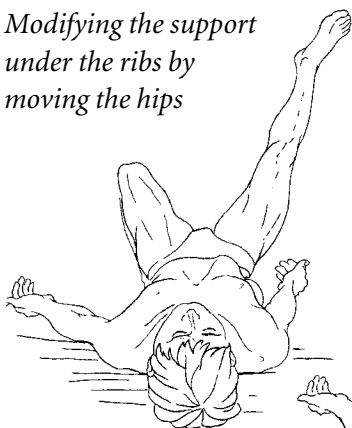
Slowly turn your head to the right or left. Make easy movements, without forcing it. The goal is not to turn your neck as far as possible, but to feel that, for example, as you turn your head to the right, you also move your right thorax (especially the top part) and bring your ribs more onto the cushion.



The ribs should get pushed back a little, curved a little more. Repeat this several times, and feel how you need to moderate the pressure of the cushion on the ribs. It is more important to vary the movement or increase/decrease the pressure during a repetition than to go further.

Modifying the support under the ribs by moving the hips

Bring the hips, knees, and ankles into flexion, with both feet flat on the floor. Lift the right foot while gently “unfolding” your knee.

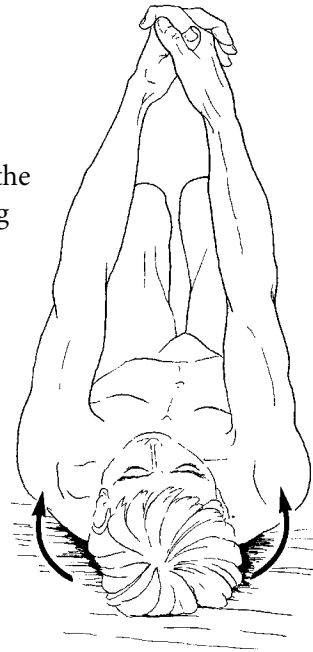
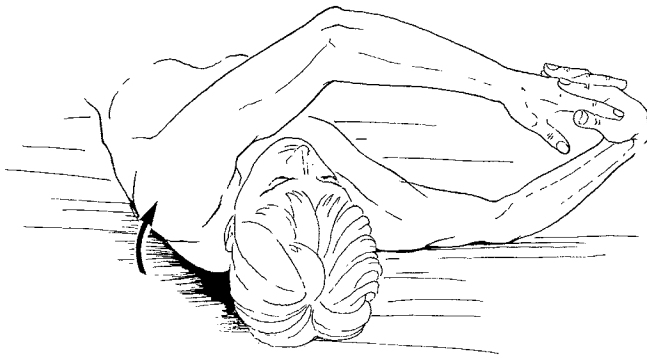
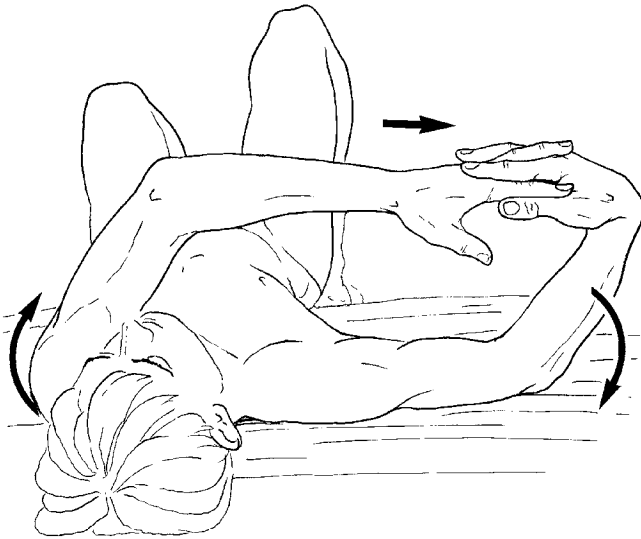


With the foot pointing upward, trace little circles in the air. They should be no more than 20cm (8 inches) in diameter. This is enough to help you feel how the pelvis and ribs (especially the lower ribs) are supported differently on the cushion. Here again, the important thing is not to move the leg fast or to trace wide circles, but to do the circles in order to move the ribs.

Repeat this movement about 10 times.

Modifying the support of the ribs by moving the arms

With your two hands joined and fingers intertwined, place the arms above your chest pointing upward while gently tensing your elbows. Focus on how you can pull your shoulder blades away from the floor.



Then, move both hands together to the right and then to the left, alternately using the flexion of one of the elbows so that the flexed arm pulls the straightened arm.

As you become more flexible, try to pull and lift the opposite shoulder blade off the ground.

Notice again how the ribs (this time the middle ribs) are pushed back and deformed against the outline of the cushion as the pressure changes with the movement of the arm. Repeat this movement about 10 times.

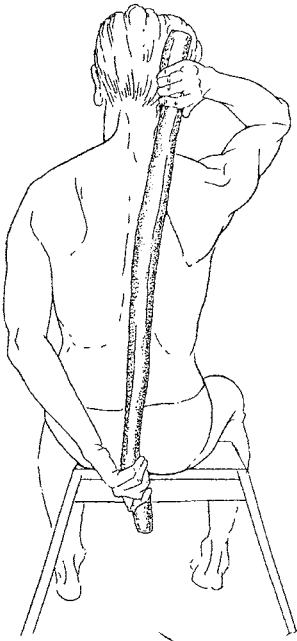
When you finish this exercise, stretch as much as possible. Feel how the ribs touch the ground and how this feeling has changed since before the exercise. How is it on the right, on the left? How are you positioned? What does the structure that you lean on (cushion, floor) feel like? When you breathe into your ribs, how is it different on each side? Now start again, but this time begin with the other side. Then, get up and feel how your costal breathing has changed.

This whole exercise provides much greater mobility of the ribs, especially in the back, but also indirectly in the front. It allows you to address the costal breathing shown on pages 189–199 in a much more effective way.

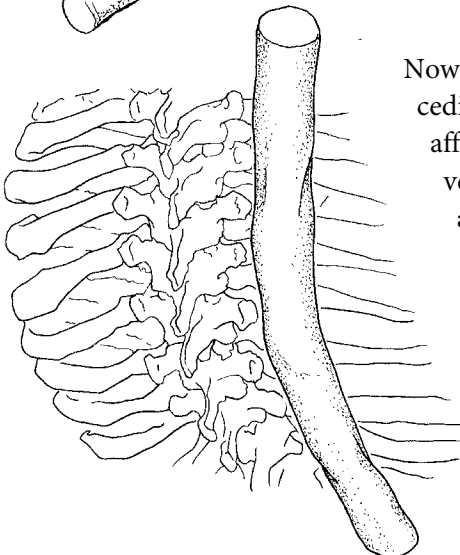
2. Mobilizing the articulations between the ribs and vertebrae

This time you have to look for movement in an area that is much closer to the spine. To mobilize this area, you need to have a thin object (about 50cm [20 inches] in length) which you can press against. This can be a soft object, such as a small rolled-up towel, or a hard object, such as a stick with a small diameter (no more than a few centimeters).

Again, stretch out on the ground and place the object on one side of the thoracic spine, about 6cm (2.5 inches) from the spinous processes.



The object should be just outside the transverse processes, at the spot where you feel the ribs start.



Now do the same movements described on the three preceding pages. The new object that you press against will affect the mobility in the joints between the ribs and vertebrae. The movement will be felt much more clearly at the middle of the back. In daily life, these barely move. When their capsules and ligaments are mobilized, you will become very aware of the sensations in the back and thorax at a specific area. As you become aware of this new mobility there, you will be able to perceive posterior costal breathing more clearly (see pages 196 and 197).